
Electronic Thesis and Dissertation Repository

2-3-2016 12:00 AM

The impact of surgical technique on coronal plane motion in total knee arthroplasty

Kevin I. Perry, *The University of Western Ontario*

Supervisor: Dr. James Howard, *The University of Western Ontario*

A thesis submitted in partial fulfillment of the requirements for the Master of Science degree in Surgery

© Kevin I. Perry 2016

Follow this and additional works at: <https://ir.lib.uwo.ca/etd>



Part of the [Orthopedics Commons](#)

Recommended Citation

Perry, Kevin I., "The impact of surgical technique on coronal plane motion in total knee arthroplasty" (2016). *Electronic Thesis and Dissertation Repository*. 3514.
<https://ir.lib.uwo.ca/etd/3514>

This Dissertation/Thesis is brought to you for free and open access by Scholarship@Western. It has been accepted for inclusion in Electronic Thesis and Dissertation Repository by an authorized administrator of Scholarship@Western. For more information, please contact wlsadmin@uwo.ca.

Abstract

Abstract There are two predominant techniques used by most surgeons to perform total knee arthroplasty (TKA): gap balancing (GB) and measured resection (MR). The purpose of the current study was to observe if surgical technique has an effect on post-operative coronal plane alignment of the knee throughout range of motion (ROM) and to observe if surgical technique has an effect on tibial and femoral component migration. This was a randomized, prospective controlled trial. Twenty-three patients (24 knees) were enrolled: twelve knees in each group. All knees showed migration of their components from the initial radiostereometric analysis (RSA) to their RSA at 6 months. Migration was similar for both groups, but in the GB group, the tibial component internally rotated whereas the measured resection group externally rotated ($p=0.03$). There was no difference between the GB group and the MR group in terms of coronal plane balance throughout ROM exhibited post-TKA implantation ($p=0.56$). Our data demonstrated that post-operative coronal plane alignment throughout ROM of the knee is most easily predicted by pre-implant operative coronal plane alignment.

Keywords: gap balancing, measured resection, component migration, total knee arthroplasty

Co-Authorship Statement

Jamie Howard, M.D. – Involved in study design, performing the surgeries in the measured resection group, data collection, data analysis and editing of the thesis.

Brent Lanting, M.D. - Involved in study design, performing the surgeries in the measured resection group, data collection, data analysis, and editing of the thesis.

Matthew Teeter, Ph.D. - Involved in study design, performing the RSA data collection, data analysis, and editing of the thesis.

Acknowledgements

I would like to start by thanking my mentors throughout this project and really my entire year of fellowship, Dr. Jamie Howard and Dr. Brent Lanting. Without your guidance and generosity this project would not have been possible. I am truly grateful for the both the time and effort spent on guiding me through this journey and ensuring that this project came to fruition.

I would also like to thank Dr. Matthew Teeter for all of his help throughout this year and on this project. He spent considerable time on the RSA portions of this project and without his help this project would not have been possible.

I would like to thank Janice Sutherland for all of her guidance and work on the course curriculum portion of the Masters of Science program. I realize that this program is in its infancy, but due to her incredible diligence and organization, the program has the appearance that it has been in place for many years.

Lastly, I would like to thank my wife, Maggie, for supporting me while I've worked on this project over the course of this year and beyond. Her patience and abilities with our 4 children are something that I find invaluable and I treasure immensely. In that respect, I would like to dedicate this thesis to Maggie and my four beautiful girls, Ava, Mckenzie, Charlotte, and Hadley.

Table of Contents

Abstract	i
Co-Authorship Statement	ii
Acknowledgements	iii
Table of Contents	iv-vi
List of appendices	vii
List of Figures	viii
List of Abbreviations	ix
1. Introduction	1
1.1 Osteoarthritis	1
1.2 Basic Knee Anatomy	1
1.3 Treatment Options For Osteoarthritis	3
1.4 Principles of Total Knee Arthroplasty	4
1.5 Radiostereometric Analysis (RSA)	6
1.6 Computer-assisted Navigation	7
1.7 Controversy in TKA: Gap Balancing vs. Measured Resection	8
1.8 Gap Balancing in TKA	9
1.8.1 Gap Balancing: The technique	10
1.8.2 Advantages/Disadvantages of the Gap Balancing Technique	13
1.9 Measured Resection in TKA	14
1.9.1 Measured Resection: Technique	15
1.9.2 Axes of the Femur	16
1.9.3 Advantages/Disadvantages of the Measured Resection Technique	18

1.10	Comparing Gap Balancing and Measured Resection Techniques	19
1.11	The Hybrid Technique	21
1.12	Can We Achieve What We Set Out To Do?	22
1.13	Unanswered Questions	23
2.	Materials and Methods	26
2.1	Patient Recruitment	26
2.2	Surgical Technique: Measured Resection	27
2.3	Surgical Technique: Gap Balancing	29
2.4	Navigation Curves	30
2.5	Principal Component Analysis	32
2.6	RSA	35
2.7	Power Analysis	36
3.	Results	37
3.1	Clinical Outcomes	37
3.2	Coronal Plane Balance During Knee Flexion	37
3.3	Implant Migration	39
4.	Discussion	42
5.	Conclusion	45
	References	48
	Appendices	52
	Appendix A	52

Appendix B	53
Appendix C	54
Curriculum Vitae	55

List of Appendices

Appendix A: Power Analysis

Appendix B: Copyright Permission

Appendix C: Knee Society Data Sheet

List of Figures

Figure 1. Anatomic depiction of the knee	2
Figure 2. Varus, valgus, neutral alignment	3
Figure 3. Flexion gap, gap balancing knee	10
Figure 4. Axes of the Femur	14
Figure 5. Lateral Condylar lift-off	18
Figure 6. AP radiograph of a TKA	24
Figure 7. Preimplantation Navigation Curve	30
Figure 8. Preimplantation Matlab Curve	32
Figure 9. PC Curve Representation	34
Figure 10. Post Implantation Navigation Curve	38
Figure 11. Postoperative Matlab Curve	39
Figure 12. Migration of the Femoral Component	40
Figure 13. Migration of the Tibial Component	41

List of Abbreviations

OA (osteoarthritis),
TKA (total knee arthroplasty),
MR (measured resection),
GB (gap balancing),
ACL (anterior cruciate ligament),
PCL (posterior cruciate ligament),
MCL (medial collateral ligament),
LCL (lateral collateral ligament)
ROM (range of motion)
PROM (passive range of motion)
PC (principal component)
CR (cruciate retaining)
PS (posterior stabilized)
ANOVA (analysis of variance)
AP (anteroposterior)

1 Introduction

1.1 Osteoarthritis

Arthritis is defined as inflammation of one or more joints. Osteoarthritis (OA) is the most common form of arthritis, affecting millions of people worldwide(1). It is characterized by gradual and progressive breakdown of the cartilage between the bones in the affected joint. Though OA can affect any joint in the body, it most commonly affects the knees, hips, hands, and spine. Symptoms of OA include joint pain and stiffness, decreased function of the joint, swelling, and grinding or cracking with joint movement. The diagnosis of OA is typically made based on the classic symptoms (as listed above), physical exam, and X-ray examination. X-ray examination typically reveals joint space narrowing of the affected joint, osteophyte formation on the bone adjacent to the joint, and in severe cases, subchondral cyst formation below the joint surface.

1.2 Basic Knee Anatomy

One of the most common areas of the body to be affected by OA is the knee. The knee is the largest joint in the body and consists of bone, cartilage (and meniscus), ligaments, tendons, synovium (joint lining), joint capsule, and synovial fluid(2). Specifically, the knee is made up by the distal femur, the tibial plateau, the patella, the fibular head, the medial and lateral menisci, the anterior and posterior cruciate ligaments, and the medial (tibial) and lateral (fibular) collateral ligaments (Figure 1). The cruciate ligaments are important stabilizers of the tibia on the femur. The anterior

cruciate ligament (ACL) resists anterior motion of the tibia on the femur while the posterior cruciate ligament (PCL) resists posterior motion of the tibia on the femur.

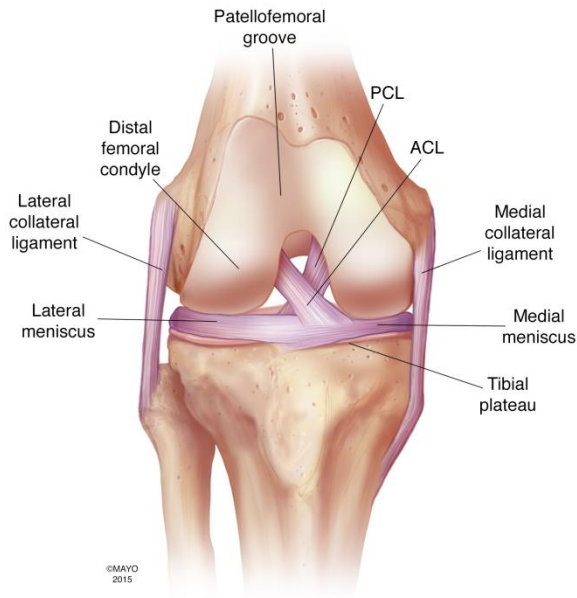


Figure 1. Anatomic depiction of the knee

Genu varum (varus) and valgum (valgus) are terms used to describe the position of the knee (3). A varus knee is commonly referred to as being “bowlegged” while a valgus knee is commonly referred to as being “knock-kneed” (Figure 2). Typically, in a varus knee, the MCL and medial knee structures are tight while the LCL and lateral knee structures are more lax. Conversely, in a valgus knee, the LCL and lateral knee structures are tight, whereas the MCL and medial knee structures are loose.

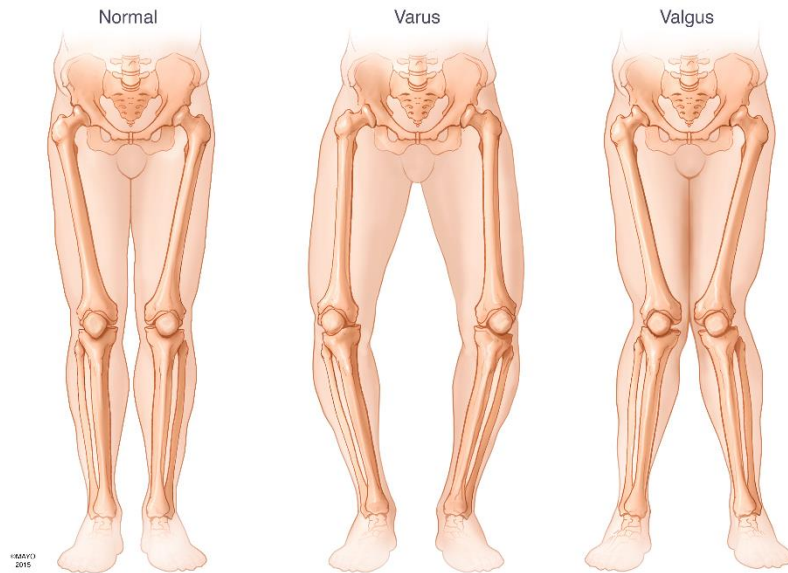


Figure 2. An illustration demonstrating neutral (normal), varus, and valgus alignment of the lower extremity.

1.3 Treatment Options for Osteoarthritis

The first-line treatments of OA are numerous and non-operative. They include weight loss (to minimize stress across the joint), non-steroidal anti-inflammatories (to reduce joint inflammation), low-impact aerobic exercise, Glucosamine-Chondroitin supplementation, steroid or viscosupplementation injections into the joint, and bracing (4). Though these modalities can often mitigate some of the symptoms associated with OA, they cannot reverse the effects of OA and in severe cases, do not provide long-lasting or effective relief. In patients who have exhausted and failed these non-operative treatments, two surgical options exist. In younger patients (typically patients <40 years of age), a high tibial osteotomy (HTO) remains a good option. In this procedure, an osteotomy (controlled break in the bone) of the proximal tibia is made and the

alignment of the lower extremity is shifted so that weight bearing through the knee is placed in the unaffected tibio-femoral compartment. For example, in a varus knee, where the weightbearing area is through the medial compartment, a HTO would be performed to shift the alignment of the lower extremity to neutral or even slightly valgus to unload the medial compartment. In older patients, or in patients in whom a HTO is a relative contraindication (arthritis involving more than one compartment of the knee, smokers, patients >40), the best surgical option is knee replacement in the form of a partial (unicompartmental knee arthroplasty, or UKA) or total (total knee arthroplasty, or TKA) replacement.

1.4 Principles of Total Knee Arthroplasty

Total Knee Arthroplasty (TKA) is a highly successful surgical treatment for end-stage arthritis of the knee(5). Though some of the nuances of TKA are argued, there are many basic principles of TKA that surgeons adhere to. The first principle that is imperative to achieve success in TKA is achieving an adequate exposure of the knee. Though numerous approaches to the knee have been described and are utilized, the workhorse approach for performing TKA is the median parapatellar approach. Nevertheless, the key to any approach is that the surgeon can safely visualize the knee in order to carry out all of the steps of a TKA.

The goal of TKA is to end up with a painless knee that is stable, achieves full extension, and flexes to greater than 90 degrees. To achieve this, most surgeons agree that the pre-operative deformity (varus or valgus) should be corrected back to neutral

alignment. The mechanical axis is defined as a line drawn from the center of the femoral head to the center of the talus. In a neutral knee, the mechanical axis should pass through the center of the knee. In a varus knee, the mechanical axis passes through the knee medial to the midline whereas in a valgus knee, the mechanical axis passes through the knee lateral to the midline. The gold-standard is to achieve a neutral mechanical axis after TKA so that the mechanical axis passes through the center of the knee as malalignment may negatively affect implant function and lead to early implant failure (6-8).

Balance of the soft-tissues around the knee is another goal of TKA surgery (9). Balance is defined as creating an equal and symmetric space between the femur and the tibia on both the medial and lateral aspects of the joint in both flexion and extension. The space between the femur and the tibia can be tested in a variety of ways, all of which involve placing a varus and valgus stress on the knee and assessing how much the lateral and medial joint space opens. When these spaces are equal and symmetric, the knee is said to be balanced and when these spaces are discrepant, the knee is said to be imbalanced and further soft-tissue balancing is often needed. It is important to remember, however, that imbalance can occur in two ways: first, if the medial and lateral spaces are unequal in either flexion or extension, or both. And second, if the medial and lateral spaces are symmetric, but unequal in flexion and extension. When the knee is balanced, the soft-tissues around the knee are well-tensioned and the knee is said to be stable. Balance of the soft-tissues around the knee and stability of the knee are congruous with one another and these terms are often used interchangeably.

In varus knees, often the soft-tissues around the medial aspect of the knee have contracted and the lateral soft-tissues are relatively lax. After the bony resections have been made in these knees, it is quite common for the surgeon to have to release some of the tight medial structures to open the medial joint space in both flexion and extension to create a space medially that is equal to the space laterally. The exact balance of the knee is subjective and varies from surgeon to surgeon as does the exact sequence of soft-tissue releases. Nevertheless, all surgeons attempt to create a symmetric space between the femur and tibia with the knee in full extension and at 90 degrees of flexion to improve patient outcomes and implant longevity (10). Despite meticulous attempts to create equal gaps in flexion and extension, however, surgeons are not always able to achieve this (11).

1.5 Radiostereometric Analysis (RSA)

Radiostereometric analysis, or RSA, is a research technique developed by Selvik et al (12) that has been modified over the years for study of migration of orthopedic implants. RSA utilizes X-ray from two different directions at the same time to create a “stereo” image. These images are used in conjunction with a cage with control marker and fiducial to calculate a 3-D coordinate system. To create a reference to the prostheses, the surgeon must implant a number of tantalum beads into the surrounding bone at the time of surgery (Figure 6). These beads are then used as reference points to detect changes in implant position over time. With this technology, surgeons are able to

detect differences in implant migration and wear patterns of TKA based utilizing different surgical techniques or targeting different limb alignment positions.

1.6 Computer Assisted Navigation

Computer assisted navigation is an surgical method of improving implant position and overall limb alignment in TKA (13). Though there are multiple different navigation systems, in TKA the most commonly utilized system is an image-free system. There are 3 primary components of the image-free system: a computer, a tracking system, and rigid body markers. The computer controls the coordination of inputs of reference points off the patient during surgery. The tracking system has a camera that is able to pick up movements from trackers utilized in the surgical field. This tracking system is then able to input different points of reference into the computer system. The rigid body markers are fixed points in the surgical field (usually fixed rigidly to bone) that serve as reference points for the computer and the dynamic trackers. Utilizing different reference points from the surgical field, the computer is able to generate a virtual 3-dimensional model of the patient's anatomy and implant position can be optimized according to this virtual 3-dimensional model. Similarly, the data points collected by the navigation system are able to demonstrate overall alignment of the knee throughout a ROM. In other words, the system can provide overall limb alignment throughout the flexion/extension arc of motion, generating a so-called alignment curve. These

alignment curves can, in turn, be interpreted and compared utilizing different existing software programs.

1.7 Controversy in TKA: Gap Balancing vs. Measured Resection

Though TKA is a highly successful and durable operation to relieve pain associated with end-stage arthritis of the knee as well as improve function and quality of life, as many as 1 in 5 patients are dissatisfied with their TKA after surgery (14). In the first five years after TKA, instability is equal to infection as the most common causes for revision TKA (15, 16). Similarly, instability has been shown to account for 22% of TKAs revised after five years (17, 18). Instability can be caused by many things, but is typically a result of poor soft-tissue balancing, component malrotation, or both (19, 20). As such, it is clear that the management of soft-tissues and correct femoral component rotation are imperative to the success of TKA.

The standard of care objectives for TKA surgical technique are 1) realignment of the lower extremity to a neutral mechanical axis, 2) restoration of the joint line, 3) obtaining well-fixed components with proper alignment in all three planes (coronal, sagittal, and axial) and 4) correct soft-tissue balancing around the knee in both flexion and extension. To achieve these goals, there are two modern techniques utilized by the majority of surgeons: gap balancing (GB) and measured resection (MR).

Over the last several decades both of these techniques have evolved into effective, reproducible means for performing total knee arthroplasty. Multiple studies have been done comparing the techniques (21-23), but these studies have not been

able to reproducibly show superior outcomes with either technique in terms of patient satisfaction or knee durability.

1.8 Gap Balancing in TKA

The gap balancing technique was initially developed at a time when there were very few antero-posterior femoral sizes available. A larger posterior femoral condylar resection was often necessary to accommodate the smaller femoral prosthesis if there was a mismatch between the femoral anatomy and available prosthesis. In order to avoid a flexion/extension mismatch and the associated instability associated with it, surgeons resorted to resecting less proximal tibia to fill the flexion space. After creation of this balanced flexion space, the extension balance was assessed. If the flexion balance required resection of the posterior condyles and resultant marginal tibial cuts, the extension space could be tight and necessitate additional distal femoral bone resection to create symmetric flexion and extension spaces. The net result was a balanced TKA, but with an elevated joint line. Current knee designs offer a multitude of femoral component sizes. Minimizing proximal tibial resection is now no longer necessary as over-resection of the posterior femoral condyles is less common. Therefore, raising the joint line is less common with the modern GB technique.

Modern gap balancing surgeons vary in terms of whether the flexion space is managed first or the extension space. In general, surgeons who use this technique describe a primary objective of creating symmetric rectangular spaces in both flexion and extension. The thought is that setting femoral rotation based on the tibial resection

and soft-tissue tension rather than fixed femoral anatomic landmarks creates a more consistently balanced knee and respects the patient's unique anatomy in a more clinically meaningful way.

1.8.1 Gap Balancing: *Technique*

The fundamental principle of the gap balancing technique relies on ligamentous releases prior to making any bony resections. There are two primary methods to perform a gap-balanced total knee arthroplasty. The first (and more common) method balances the knee in extension first and the second method balances the knee first in flexion. Currently the standard of care is a proximal tibial resection at 90 degrees perpendicular to the mechanical axis of the tibia. The amount of posterior slope is determined by the specific design of the implants being used and the surgeon should be familiar with this intra-operatively. Typically, 8-10mm of tibia is resected off the least affected side (i.e. the lateral side in a varus knee).

In the extension-first technique, the proximal tibial resection is made at a 90-degree angle to the mechanical axis of the tibia and the distal femoral resection is carried out utilizing intramedullary instrumentation in physiologic valgus. The order of proximal tibial and distal femoral resections can be carried out according to surgeon preference. Osteophytes are then removed and soft tissue releases performed to create an equal medial and lateral extension space. Once the extension space is symmetric and a rectangular gap is created, the knee is brought into flexion. Implant specific instrumentation or laminar spreaders can be used to tension the collateral ligaments

symmetrically. Once the ligaments are tensioned symmetrically, the anteroposterior cutting block is placed. The rotation of the femoral component rotation is set perpendicular to the proximal tibial resection (Figure 3). Rotation of the femoral component occurs around the y-axis of the femur and is generally carried out with the knee flexed to 90 degrees to provide a symmetric space between the cutting block and the proximal tibial resection (Figure 3). The antero-posterior (AP) position of the cutting block on the distal femur is selected to create a space of equivalent magnitude to the extension space. Anatomic landmarks like the transepicondylar axis (TEA), posterior condylar axis, and the AP axis of the femur (aka Whiteside's line) can be used as secondary checks, but are not the driving force for setting femoral component rotation. In the end, symmetric rectangular spaces of equal magnitude are created in both flexion and extension. The size of the femoral component is selected only after the soft tissues are appropriately tensioned, the flexion space is made equivalent to the extension space, and appropriate rotation is incorporated.

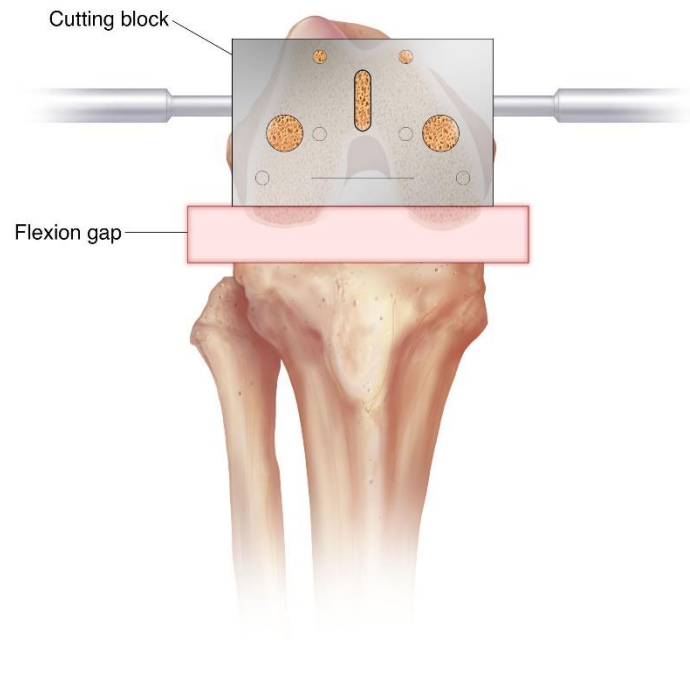


Figure 3. In the gap balancing technique, rotation of the femoral cutting block is set to create an equal space medially and laterally in flexion based on the proximal tibial resection.

In the flexion first technique, once the tibial resection has been made, the knee is brought into flexion and a tensioner is inserted to tension the collateral ligaments around the knee are balanced so that there is a rectangular space between the resected tibia and the posterior femoral condyles. This may also be conducted in a stepwise fashion, with provisional posterior condylar cuts made to facilitate posterior osteophyte removal prior to tibial resection and subsequent balancing of the knee in flexion. The knee is then brought into extension and a tensor placed so that the rectangular

extension space is equal to the flexion space and the distal femur can be resected to match the rectangular space created in flexion.

A neutral tibial resection should be considered in the gap balancing technique as a varus tibial resection may place the femoral component in relative internal rotation (to a neutral resection) and a valgus tibial resection may place the femoral component in relative external rotation. Nevertheless, the clinical significance of relative internal or external femoral component rotation has not been established.

1.8.2 Advantages/Disadvantages of the Gap Balancing Technique

Proponents of the gap balancing technique advocate that femoral component rotation respects the soft tissues of the knee and that perhaps greater coronal plane stability is achieved than with the measured resection technique. Katz et al (24) used 8 frozen cadaver knees and showed that the transepicondylar axis was less predictable than using the AP axis of the femur for the gap balancing technique. The authors concluded that femoral component rotation may be more reliable when using gap balancing techniques as opposed to fixed femoral anatomic landmarks.

The first potential disadvantage of this technique is that the joint line may be elevated when a large flexion gap dictates that a larger distal femoral resection be made (25). This occurs most commonly in the setting of a pre-operative flexion contracture where more distal femur must be resected than will be replaced by the femoral prosthesis. Joint line elevation has been shown to contribute to joint instability in mid-flexion, even when the joint is stable in full extension and in flexion(17). Nevertheless,

modern implant design and sizing variability have likely diminished the number of knees requiring joint line elevation for flexion/extension balance. Second, as previously described, femoral component rotation is heavily dictated by the proximal tibial resection. When a varus tibial resection is made, the femoral component may be placed in a relatively internally rotated position. Similarly, if a valgus tibial resection is made, the femoral component may be placed in relative external rotation. The clinical significance of relative internal or external rotation of the femoral component has not been clearly established. Nevertheless, in the available literature (3)(26), the GB technique seems to create a balanced flexion space and produce symmetry of contact of the femoral and tibial components throughout a range of motion.

1.9 Measured Resection in TKA

The primary objective of the measured resection is to respect the normal anatomy of the knee and to use cutting guides to reproducibly create a neutral aligned knee with maintenance of the joint line. The technique was initially developed to accommodate cruciate retaining total knee arthroplasty designs as it was observed that maintenance of the joint line lead to better collateral and cruciate ligament function. The technique is predicated on bony resection that is equal to the amount of bone being replaced by thickness of the total knee prosthesis being inserted. In this technique, femoral component rotation is set based on anatomic landmarks of the femur, most notably the AP axis of the femur (Whiteside's line)(27), the transepicondylar axis (TEA) (9), and the posterior condylar axis (8).

1.9.1 Measured Resection: Technique

An important objective of the measured resection technique is maintenance of joint line position. To accomplish this, bony cuts are made independent of soft tissue tension. Specifically, bony resections are made in an effort to match the thickness of the prostheses being inserted as previously described. Balancing of the knee commences only after bony resections are made so that medial and lateral joint spaces are symmetric in both extension and flexion.

As bony resections are made prior to ligamentous balancing of the knee, femoral component rotation must be set based on fixed anatomic landmarks of the femur. Several bony landmarks have been described and typically, are used in combination. These landmarks include the AP axis of the femur (Whiteside's line)(27), the transepicondylar axis (TEA) (9), and the posterior condylar axis (8)(Figure 4).

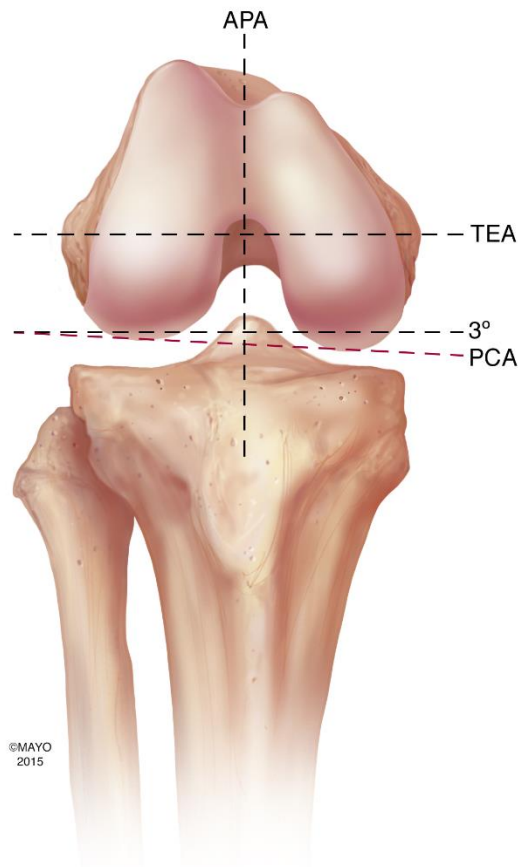


Figure 4. Diagram showing the AP axis of the femur (APA), the transepicondylar axis (TEA), and the posterior condylar axis (PCA). Note that the PCA is in 3 degrees of internal rotation relative to the TEA.

1.9.2 Axes of the Femur

The posterior condylar axis (PCA) is defined by a line that is tangential to the posterior aspect of both the femoral condyles. In the non-diseased knee, the posterior femoral condylar axis defines the neutral alignment of the knee in flexion. Tibial resection at a 90-degree angle to the mechanical axis of the tibia removes the normal varus associated with the proximal tibia and creates a relative increase in the lateral

flexion gap. As such, most total knee systems have been developed to accommodate this and have built in some external rotation (3-5 degrees depending on the system and surgeon preference) to close the lateral flexion gap. Referencing the PCA is relatively simple and in knees with normal anatomy is quite accurate (28). Many surgeons currently use the PCA as the primary anatomic landmark for the large majority of their TKAs. Nevertheless, there can be distortion of the normal anatomy in diseased knees undergoing total knee arthroplasty (29). This distortion is most evident in the hypoplastic lateral femoral condyles of many valgus knees and in knees with varus tibial joint obliquity (30). Griffin et al (31) measured the posterior condylar angle (PCA) in 107 osteoarthritic knees and found that the valgus knees had an average of 5.4 degrees (range 0-10 degrees) of internal rotation relative to the transepicondylar axis. As a result of this variability, most surgeons who use a MR technique feel strongly that other anatomic landmarks should be utilized when performing a TKA on valgus knees.

The transepicondylar axis (TEA) of the knee is defined by a line from the prominence of the lateral epicondyle to the sulcus of the medial epicondyle (surgical TEA) or the ridge of the medial epicondyle (clinical TEA). Berger et al (32) demonstrated that the TEA serves as a reliable landmark for both normal and diseased knees. They demonstrated that the surgical TEA, in particular, serves as a useful landmark in defining neutral rotational orientation of the femoral component. Many authors (33-36) have described improved kinematics (both patellofemoral and femorotibial) of the knee by placing the femoral component parallel to the TEA. In

addition, utilization of the TEA has been shown to produce accurate rotation of the femoral component that leads to minimal condylar liftoff (37, 38).

The AP axis of the femur, also known as Whiteside's line, is defined by a line on the femur from the deepest point of the trochlear sulcus anteriorly to the midpoint of the intercondylar notch posteriorly. It was originally described by Whiteside and Arima (27) as an alternative to using the transepicondylar and posterior femoral condylar axes in valgus knees. In their original series, the authors found that only 1 out of 107 valgus knees required an intraoperative medialization of the tibial tubercle when the AP axis of the femur was used to set femoral rotation. In the 46 valgus knees performed where femoral rotation was set using the posterior femoral condylar axis, 6 knees (13%) required intraoperative medialization of the tibial tubercle and 4 (9%) of these had continued problems with patellar dislocation or subluxation postoperatively. The other 40 knees in the posterior condylar axis group required extensive lateral releases to allow proper patellar tracking. The authors concluded that the AP axis of the femur is a reliable method to set femoral component rotation and is easier to establish than the transepicondylar axis of the femur.

1.9.3 Advantages/Disadvantages of Measured Resection

The first advantage of the MR technique is that joint line position is preserved and is not altered based on flexion/extension space mismatch. In addition, the native anatomy of the knee is respected completely. Only bone that will be replaced with metal is resected. Multiple anatomic landmarks provide multiple different ways to

assess femoral component rotation and has been demonstrated to be more accurate than the gap balanced technique (39).

Detractors of this technique argue that defining the anatomic landmarks needed to set femoral rotation can be difficult and imprecise (5-7,10,11) and may lead to inconsistent femoral component rotation (40). As such, some feel the technique is outdated (41). Jerosch et al (42) compared the difference in the position of the epicondyles marked by different surgeons and determined the position varied among surgeons up to 22.3 mm for the medial epicondyle and up to 13.8 mm for the lateral epicondyle. Similarly, Kinzel et al (43) identified and marked the surgical epicondylar axis in 74 knees with pin holes filled with cement. An alternative method was used to set femoral component rotation and post-operative CT scans were used to assess femoral component rotation. The authors found that had the epicondylar pins been used to set femoral component rotation, the femoral component would have been put in from a range of 6 degrees of external rotation to 11 degrees of internal rotation. The authors concluded that intraoperative assessment of the TEA is unreliable and should not be relied upon as the sole determinant of femoral rotation.

1.10 Comparing Gap Balancing and Measured Resection Techniques

Considering that both the MR and GB techniques have been used by surgeons to perform TKA for decades, there is a relative paucity of literature directly comparing the techniques. Babazadeh et al. (25) performed a randomized controlled trial compared gap balancing to measured resection techniques in 107 patients and found that there

was no significant difference in femoral component rotation between the two groups. They did find, however, that the joint line was significantly raised with the gap balancing technique compared to the measured resection group. Nevertheless, there were no differences noted in terms of patient outcomes at 2-year follow up despite the raised joint line in the GB group. Similarly, Singh et al (22) randomized 52 patients to either a measured resection or gap balanced TKA and showed no difference in clinical outcomes at 2-year follow up.

Dennis et al. (44) reviewed 60 TKAs (40 done with the MR technique (20 cruciate retaining (CR) and 20 posterior stabilized (PS)) and 20 with the GB technique) using a 3-D model to determine the incidence of coronal plane instability. The average femoral condylar lift-off (Figure 5) was 1.45mm for the CR measured resection group, 1.11mm for the PS measured resection group, and 0.67mm for the GB group. They found that the incidence of femoral lift-off of 1mm or greater was 60% for the CR measured resection group and 45% for the PS measured resection group compared to 0% for the gap balancing technique. The authors concluded that rotation of the femoral component is inconsistent when using a measured resection technique. They also concluded that a gap balancing technique improved coronal plane stability and long-term wear of the total knee arthroplasty.

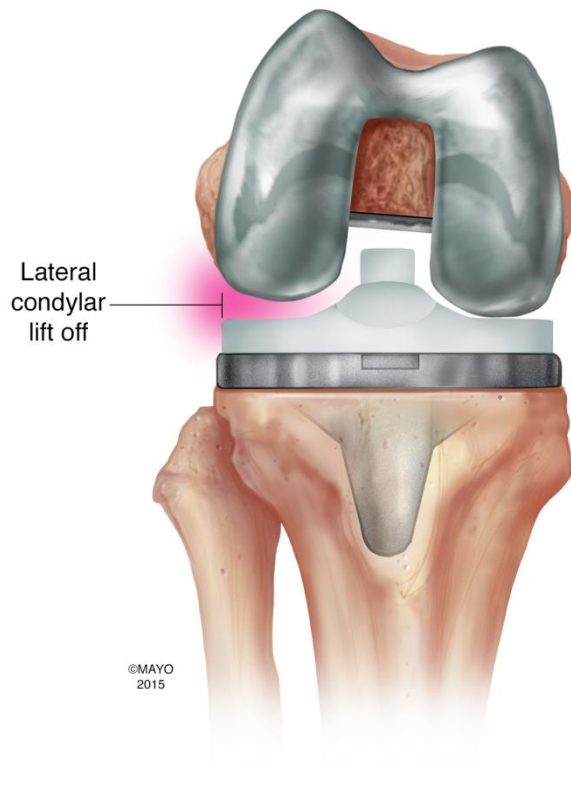


Figure 5: Coronal plane view of a TKA, demonstrating lateral condylar lift off of the femur on the polyethylene.

1.11 The Hybrid Technique

Despite the obvious differences in surgeon philosophy for the GB and MR techniques, modern total knee arthroplasty often encompasses aspects of both techniques. Specifically, in the modern GB technique, most North American surgeons base their distal femoral and proximal tibial resections on measured values to recreate the patient's normal joint line based on implant thickness. Similarly, many surgeons that describe themselves as MR surgeons utilize spacer blocks in both flexion and extension after bony resections have been made and may adjust bony resections or soft-tissue

releases based on their flexion/extension mismatch. The fundamental difference that divides the MR and GB techniques is how femoral component rotation is determined. Gap balancing surgeons in general will not override where the proximal tibia and soft tissue tension tell them to set femoral component rotation no matter what the fixed femoral anatomic landmarks may indicate. Similarly, MR surgeons base their femoral component rotation off the fixed femoral anatomic landmarks and don't let proximal tibial resection or soft tissue tension dictate where femoral component rotation should be set. Determinants of femoral component rotation set the foundation for each technique and are what really separate the two techniques today.

1.12 Can We Achieve What We Set Out To Do?

Regardless of the methodology for performing a TKA, the surgeon's ability to accurately and symmetrically balance the soft tissues around the knee may not be as accurate as we think. Griffin et al (8) studied the symmetry between the flexion and extension space in 104 knees undergoing TKA utilizing a gap balancing technique. The authors found when comparing the medial flexion gap to the medial extension gap, only 59 (56.7%) of knees were balanced within 1 mm. Similarly, when comparing the lateral flexion gap to the lateral extension gap, only 49 (47.1%) of knees were balanced within 1 mm. Inequality of at least 3 mm was found in 16% of knees medially and 25% of knees laterally. The authors concluded that despite meticulous efforts to perfectly balance the soft tissues around the knee, we aren't always accurate in achieving this.

1.13 Unanswered Questions

No matter what technique (GB or MR) a surgeon uses to perform TKA, the goals of surgery are similar: to obtain a knee that is balanced throughout range of motion (ROM), restore a neutral mechanical axis of the lower extremity, and obtain well-fixed components in proper alignment in all three planes (coronal, sagittal, and axial). Both the GB and MR techniques offer surgeons reproducible and durable methods for obtaining these goals. An understanding of the concepts of both techniques and the potential for combining key elements from each technique may facilitate optimal outcomes, but remains unproven.

Over the last decade much attention has also been given to the alignment curves of the normal and diseased knee. Joint function in TKA is generally based on average “normal” knee alignment curves. Little has been published, however, on how surgical technique affects these alignment curves of the TKA post-operatively. In other words, it is unclear if performing a TKA with either a MR or GB technique affects post-operative knee alignment through a ROM. Similarly, little has been published on surgical technique and implant migration utilizing RSA or on surgical technique and patient clinical outcomes.

Though there is currently no data to demonstrate better long-term results with either the MR or GB technique, based on the work by Dennis et al (23), there certainly is an argument being made by some surgeons that the GB technique may offer more symmetric contact of the femoral and tibial components through a ROM than the MR technique. If this is true, it is possible that implant migration may be affected by surgical

technique. Nevertheless, as the MR technique respects native anatomy completely, in theory, the alignment curves of the MR knee post-TKA should replicate native knee alignment curves better than GB TKAs. As a result, we sought to test two hypotheses that will be assessed over the short-term (this thesis) and the long-term: In the short-term, we aimed to assess if MR TKAs demonstrate post-TKA alignment curves more similar to native knee alignment curves than GB TKAs. Similarly, we aimed to determine the role of surgical technique on short-term implant migration. In the long-term, we are interested in determining if GB produces better coronal plane stability than MR after TKA.

As such, the purpose of the current study was 1) to observe if surgical technique (GB vs. MR) influences post-operative alignment curves, 2) to observe if surgical technique influences tibial or femoral component migration post-operatively.

With regard to post-operative coronal plane alignment curves, our primary hypothesis was that surgical technique does impact the coronal plane alignment of the knee intraoperatively. As the bone resections made using the MR technique are equivalent to the implant dimensions and the bony anatomy of the knee is preserved, we hypothesized that the MR technique would produce post-operative knee coronal plane alignment curves more similar to pre-operative knee alignment curves than the GB technique.

With regard to implant migration, our primary hypothesis was that the GB knee will demonstrate less component migration because of the *symmetric* articular contact in both the medial and lateral compartments of the knee throughout ROM demonstrated by Dennis et al (23). Similarly, we hypothesized that TKAs performed with a MR technique will have

an increased incidence of component migration because of an *asymmetric* articular contact in the medial and lateral compartments of the knee (i.e. the components will migrate because of asymmetric articular contact forces).

2

Materials and Methods

2.1 Patient Recruitment

Twenty-three patients (24 knees) were randomly assigned to a surgeon on the day of referral. All patients undergoing TKA were eligible for participation. Exclusion criteria included a history of alcoholism, if there was a language barrier, if the patient was pregnant or trying to get pregnant, or was undergoing bilateral, simultaneous total knee replacement. Twelve knees were enrolled in each group; according to a power analysis (Appendix 1) previously reported by Dennis et al (23). There were 5 males (6 knees) and 6 females in the GB group. There were 6 males and 6 females in the MR group. The average age in the GB group was 66 years old (range 56-77). The average age in the MR group was 70 years old (range 58-83). Each surgeon performed his standard technique: one using a MR technique, the other using a GB technique. The patella was not resurfaced in either group. The same TKA system was utilized (Triathlon®, Stryker, Mahwah, NJ) for all knees. The surgeon was blinded to this data during the surgery, and it was not used to guide surgical technique. Tantalum beads were inserted intra-operatively according to a standardized protocol, with 8 beads evenly distributed in the distal femur and 8 beads in the proximal tibia (Figure 6). The patients received standard of care physiotherapy (ROM exercises, quad strengthening, gait retraining) and physician visits post-operatively. Physician visits were carried out at 6 weeks, 3 months, and 6 months. At each of these visits, RSA analysis of component migration and clinical outcomes were recorded. The primary outcomes of this study were implant migration

utilizing RSA and coronal plane alignment of the knee during knee flexion. Secondary outcome measures were clinical outcomes for each group utilizing the (new) Knee Society Score (45).

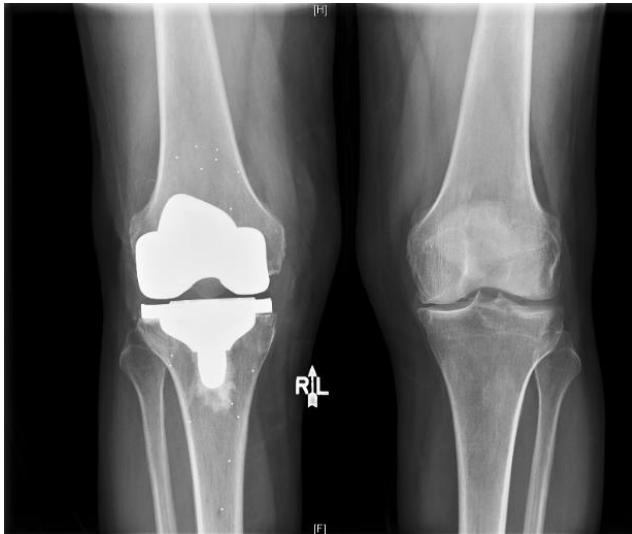

Figure 6. An AP radiograph of both knees after a right TKA with tantalum bead implantation according to a standard protocol with 8 beads in the femur and 8 beads in the tibia.

2.2 Surgical Technique: Measured resection

The TKAs in the MR group were performed consecutively by one surgeon (J.H.) according to his standard surgical approach. A tourniquet was used for all patients. A standard midline incision was made and sharp dissection carried down to the level of the capsule. A standard medial parapatellar arthrotomy was then created with the knee in flexion. A mid-coronal release of the deep MCL was completed along the medial proximal tibia. The fat pad was excised and a small amount of synovium was reflected

off the anterior femur for better visualization. At this point, a pin was placed into the distal femur so as not to interfere with the sequence of the TKA. A small incision was then made on the tibia distal to the knee incision and two pins were placed into the tibia. Femoral and tibial fiducials were then placed onto the respective pins and were registered using intraoperative navigation. Multiple anatomic landmarks on both the femur and tibia were then marked and registered utilizing intraoperative navigation. The knee was then taken through range of motion to register the intraoperative coronal plane alignment of the native knee prior to any bony or ligament resection. Care was taken to place varus and valgus stress on the knee in full extension and then the knee was taken through range of motion without application any varus or valgus stress by the surgeon. The distal femur resection was made with an intramedullary guide, as the pins for the femoral tracker were placed to avoid interference with the guide. Femoral component rotation was set at 3 degrees of external rotation relative to the posterior condylar axis for all patients as all the knees in the study population were varus knees. Intraoperative registration of the femoral and tibial resection as well as was recorded, but was not utilized to guide surgery in any way. This information was blinded to the surgeon at the time of the operation. After implantation of the final components, the knee was once again taken throughout range of motion and intraoperative coronal plane alignment of the knee recorded.

2.3 Surgical Technique: Gap Balancing Technique

The TKAs in the GB group were performed consecutively by one surgeon (B.L.) according to his standard surgical approach. A tourniquet was used for all patients. A standard midline incision was made and sharp dissection carried down to the level of the capsule. A standard medial parapatellar arthrotomy was then created with the knee in flexion. A mid-coronal release of the deep MCL was completed along the medial proximal tibia. The fat pad was excised and a small amount of synovium was reflected off the anterior femur for better visualization. At this point, a pin was placed into the distal femur so as not to interfere with the sequence of the TKA. A small incision was then made on the tibia distal to the knee incision and a two pins were placed into the tibia. Femoral and tibial fiducials were then placed onto the respective pins and were registered using intraoperative navigation. Multiple anatomic landmarks on both the femur and tibia were then marked and registered utilizing intraoperative navigation. The knee was then taken through range of motion to register the intraoperative coronal plane alignment of the native knee prior to any bony or ligament resection. Care was taken to place varus and valgus stress on the knee in full extension and then the knee was taken through range of motion without application any varus or valgus stress by the surgeon. The distal femur resection was made with an intramedullary guide using standard techniques. The medial and lateral gaps were balanced first with the knee in full extension after the proximal tibial resection was made. The femoral component rotation was then set according to the proximal tibial resection and AP translation of the femoral component was set so as to create symmetric flexion and extension gaps.

Intraoperative registration of the femoral and tibial resection as well as was recorded, but was not utilized to guide surgery in any way. This information was blinded to the surgeon at the time of the operation. After implantation of the final components, the knee was once again taken throughout range of motion and intraoperative coronal plane alignment of the knee recorded.

2.4 Navigation Curves

Computer assistance (Precision 4.0, Stryker, Mahwah NJ) was used to assess and record range of motion and the three dimensional position through this range of motion as well as component position. (45). Intra-operatively, the passive motion pathways were recorded using the active trackers of the navigation system (Fig 7).

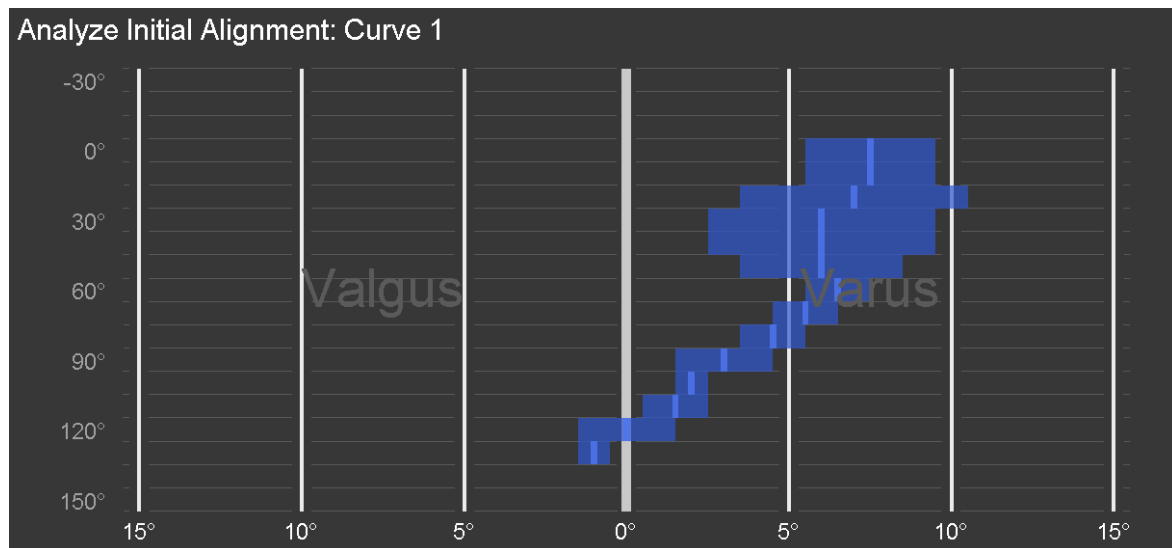


Figure 7. An example of the curve generated by the intraoperative navigation (Precision 4.0, Stryker, Mahwah NJ) for the native knee throughout range of motion for a single

patient. The Y-axis represents knee flexion and the X-axis represents overall coronal plane alignment. In this example, the coronal plane alignment starts in 7-8 degrees of varus and approaches neutral as the knee goes into deeper flexion.

Post-operatively, the intraoperative curves generated from the navigation system (Precision 4.0, Stryker, Mahwah NJ) were extracted and a custom Matlab® program (The Mathworks, Natick, MA, USA) was used to calculate the three-dimensional (3D) angular movement of the knee for the pre and post-implant state (Figure 8). The exact methodology has been previously described (46) and was followed meticulously. Briefly, the coronal plane alignment of the knee during passive range of motion is extracted for both the pre- and post-implant states. The program then generates curves that were plotted to illustrate coronal plane alignment angles on the x-axis, and the range of flexion on the y-axis to match the format of the navigation system (Figure 8).

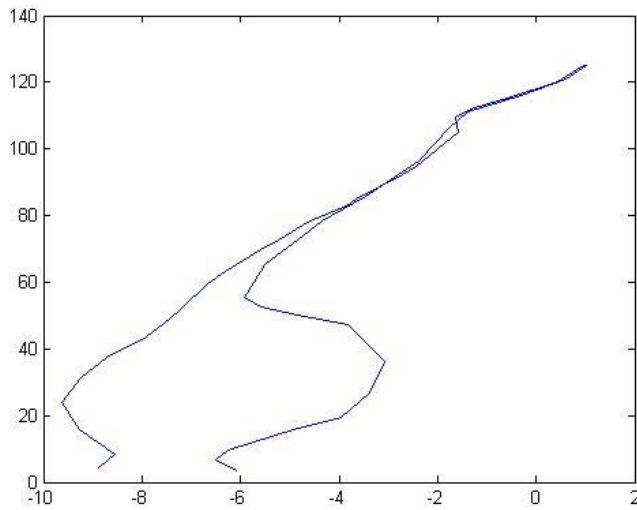


Figure 8. This is an example of the preoperative curve generated by the Matlab® program (The Mathworks, Natick, MA, USA) from the intraoperative navigation curve. Again, the y-axis represents flexion (in degrees) and the x-axis represents coronal plane alignment (negative values are varus and positive values are valgus). Note that in this diagram, full extension is at the bottom of the Y-axis and two curves are generated demonstrating the variability in alignment with varus/valgus stressed placed on the knee in full extension.

2.5 Principal Component Analysis (PCA)

Principal component analysis (PCA) is a multivariate statistical analysis technique that characterizes patterns of joint alignment throughout a range of motion. Principal component analysis was appealing to analyze the intraoperative alignment curves because it has previously been described (46, 47) and intraoperative curve patterns have been shown to fall within one of several patterns (46). Using a validated custom program in Matlab® (The Mathworks, Natick, MA), the original data was recorded,

interpreted, and displayed according the method previously described by Deluzio and Astephen (48). The first four PCs (PC1-PC4) described by Deluzio and Astephen were used for analysis of our data, and all pre and post-implant alignment curves were projected onto each of these 4 patterns to calculate PC scores, which quantify how closely the original alignment curve matches the pattern described by each PC.

The principal component curves have been previously described by Young et al (46) and is beyond the scope of this thesis. Briefly, however, the authors described PC1 as the overall magnitude of the knee varus angle from full extension to full flexion. High PC scores described varus angles through the passive range of motion (PROM), and low scores described valgus angles throughout PROM. Similarly, PC2 describes a difference between the varus/valgus angle at low and high flexion angles. High PC2 scores are associated with a change from more varus to valgus angles throughout the flexion range (what the authors described as a “frontal plane drift pattern”), while low PC2 scores are associated with a change from more valgus to varus throughout the range (i.e. “an inverted drift pattern”). In other words, a knee might start off at 7 degrees of varus in full extension, but end up in 5 degrees of valgus in full flexion. This pattern would be described with a high PC2 or a frontal plane drift pattern. PC3 describes a dominant “C-shaped pattern” within the data, with high PC3 scores characterizing curves with more varus angles at full extension and flexion and more valgus at mid flexion. Low PC3 scores describes the opposite pattern with valgus at full extension and flexion and more varus in mid-flexion (an “inverted C-shape”). PC4 describes an “S-shaped pattern” where high PC4 scores characterize a pattern of more valgus angles at full extension, transitioning

to relative varus at early flexion to relative valgus in later flexion, and ending relatively more varus in full flexion. Low PC4 scores described the opposite, or an “inverted S-shape” (Figure 9).

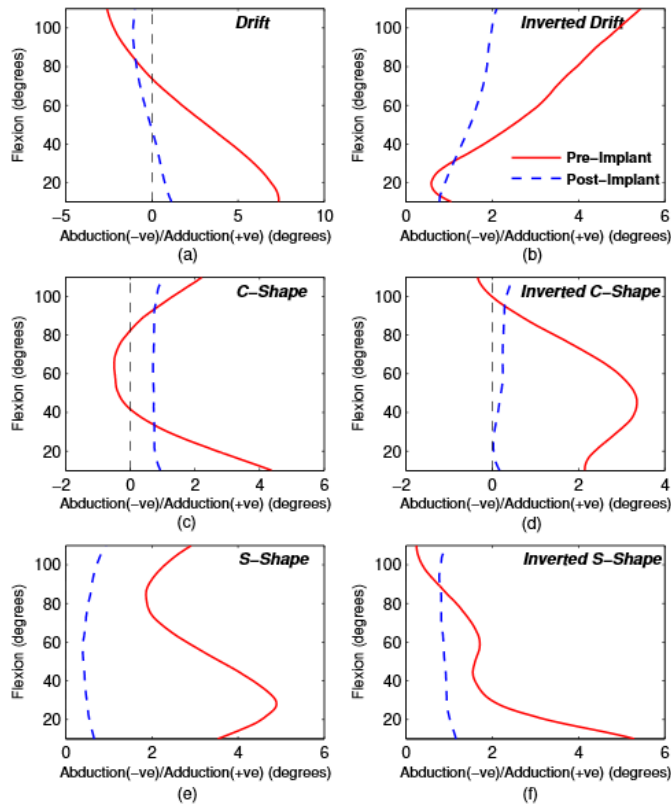


Figure 9. Graphic representations of the different PC curves described by Young et al (46), reprinted with permission from JOR (Appendix C) .

Pre- and post-implant knees were categorized by the group to which they were assigned: measured resection and gap balanced. Two-tailed Student’s paired t-tests were used to examine PC score differences between pre and post-implant states for both groups and a one-way ANOVA was used to examine if the principal component

scores were significantly different from zero to assess if the PC pattern was maintained pre- to post-implant.

2.6 RSA

Using the tantalum beads placed during TKA implantation the patients underwent RSA to determine component position relative to the tantalum beads. This was carried out at 6 weeks, 3 months, and 6 months. A 2D-3D registration model was created to register the knee position from the RSA, utilizing the tantalum markers. A model-based RSA technique was used to detect implant position and orientation by matching its actual and virtual projections in both radiographic views. To calculate virtual projections of the implant, we utilized CAD (computer-aided design) model of the Triathlon knee provided by the manufacturer (Stryker). Component migration over time was recorded utilizing RSA. Values were recorded as mean \pm standard deviation (minimum to maximum). Positive directions for the translations were defined as lateral in the axial (X) plane, superior in the coronal (Y) plane, and anterior in the sagittal (Z) plane. Positive directions for the rotations were defined as anterior tilt about the axial (X) axis, external rotation about the coronal (Y) axis, and valgus rotation about the sagittal (Z) axis.

2.7 Power Analysis

The study was powered according to the power analysis by Dennis et al (3) for coronal plane imbalance between the MR and GB techniques in which coronal plane balance was compared using a repeated-measures two-way ANOVA with the Tukey post-hoc test; with 2 means to compare, 12 patients in each group, and 5 different flexion angles, (assuming a within-group SD of 0.60 mm based on the prior work by Dennis et al (3), $\alpha = 0.05$ (two-tailed) and power 0.80).

3 Results

3.1 Clinical Outcomes

All patients showed improvements in their overall function. Pre-operatively, patients in the MR group had average Knee Society Scores (KSS) of 46 (function), 15 (satisfaction), and 13 (expectations). Post-operatively, all patients in the MR group improved and had average KSS of 88 (function), 35 (satisfaction), and 13 (expectations). Similarly, pre-operatively, all patients in the GB group had an average KSS of 44 (function), 13 (satisfaction), and 12 (expectations). All patients in the GB group improved post-operatively with average KSS of 89 (function), 34 (satisfaction), and 12 (expectations). There was no statistically significant difference in pre-operative ($p=0.56$) or post-operative ($p=0.54$) KSS between the two groups.

3.2 Coronal Plane Balance During Knee Flexion

Of the 24 TKAs, all 24 contained complete matched-pair pre and post-implant adduction angle data through a full range of motion (defined as at least 10-110 degrees). Twenty-three (96%) out of 24 knees were varus and 1 knee was in neutral alignment preoperatively. The variability in the varus/valgus-angle curve data was explained by the first four PCs in all 24 knees (100%). Pre-operatively, in the MR group, 1/12 patients exhibited an S-shaped curve, 3/12 exhibited a C-shaped or inverted C-shaped curve, and 8/12 exhibited frontal plane drift. In the GB group, no patients exhibited an S-shaped curve (or inverted S-shape), 5/12 exhibited a C-shaped or inverted C-shaped curve, and 7/12 exhibited frontal plane drift. There was no

statistically significant difference between the GB group and the MR group in terms of PC pattern exhibited pre or post-TKA implantation ($p=0.47$ and $p=0.56$, respectively). The PC score used to characterize each curve decreased in magnitude significantly between the pre and post-TKA states ($p<0.001$) though the PC pattern exhibited pre-operatively was still evident post-TKA implantation (though at a smaller magnitude) for TKAs ($p<0.043$). Though all knees exhibited a statistically significant more neutral mechanical alignment post-operatively ($p<0.006$), 21/23 (91%) of the varus knees still exhibited overall varus alignment (of smaller magnitude) postoperatively.

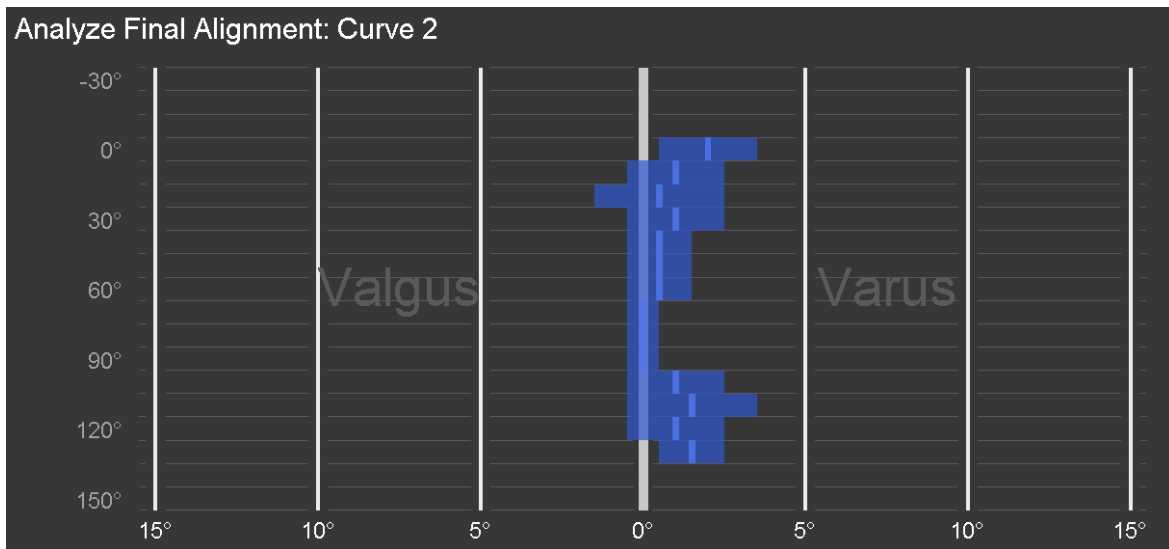


Figure 10. Post TKA implantation Intraoperative Curve. This is the same curve generated by the intraoperative navigation system (Precision 4.0, Stryker, Mahwah NJ) after the TKA has been implanted in the same patient as above. The overall coronal plane alignment has approached neutral and remains neutral throughout the flexion

arc.

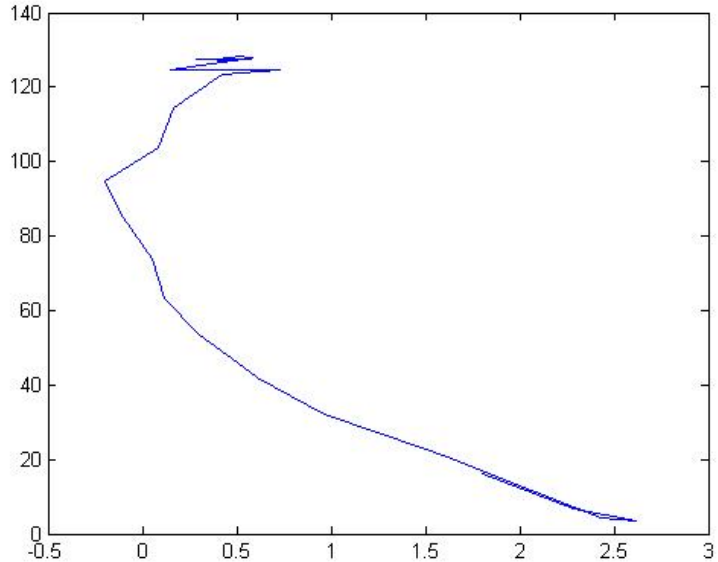


Figure 11. This is the postoperative curve generated by the Matlab® program (The Mathworks, Natick, MA, USA) for the same patient shown above. Again, the y-axis represents flexion (in degrees) and the x-axis represents coronal plane alignment (negative values are varus and positive values are valgus). This curve represents a high PC3 score or a C-shaped curve.

3.3 Implant Migration

All patients showed migration of their components relative to the tantalum beads from the initial RSA to their RSA at 6 months. Migration was similar for both the GB and MR groups with one exception: tibial component external-internal rotation. In the GB group, the tibial component internally rotated and the measured resection group externally rotated ($p=0.03$). This was the only statistically significant difference seen

between the two groups. A detailed description of the migration of the tibial and femoral components relative to the tantalum beads is provided in Figures 9 and 10, respectively.

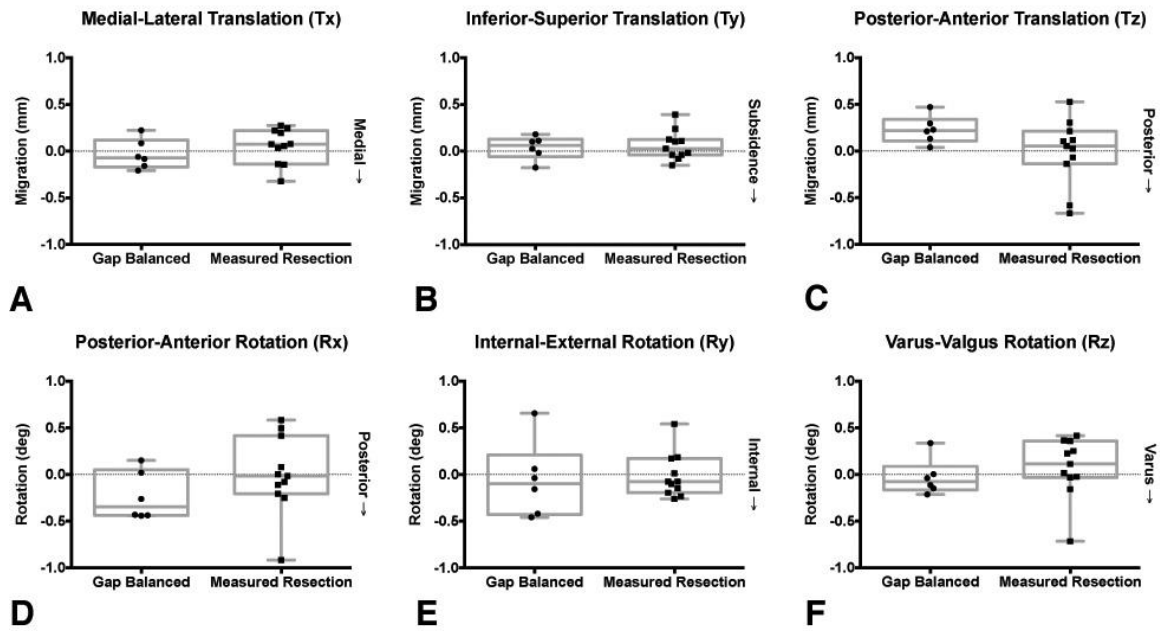


Figure 12. Migration of the Femoral Component

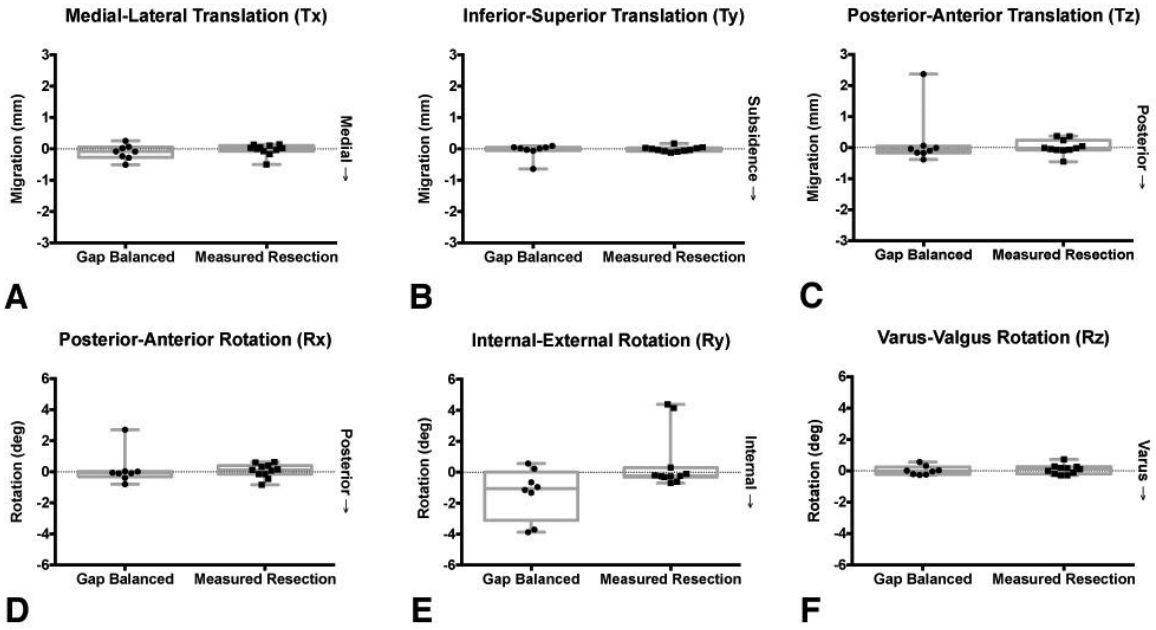


Figure 13. Migration of the Tibial Component

4 Discussion

Babazadeh et al. (25) compared 107 patients in a randomized controlled trial who underwent TKA via a gap balancing or measured resection technique and demonstrated no significant difference in femoral component rotation or clinical outcomes between the two groups. As both the MR and GB techniques have been demonstrated to deliver good clinical outcomes (22, 49), it is not surprising that no statistically significant difference in clinical outcomes between the GB and MR groups was observed in our series.

Migration tended to be quite similar for both the femoral and tibial components in both the MR and GB groups with one exception: external-internal rotation of the tibial component. Our results indicate that migration of the tibial component in the GB group tended to be into internal rotation and in the MR group, external rotation. The observed difference in implant migration may be explained by the lateral compartment being overloaded in flexion in the measured resection group forcing the tibial component into relative external rotation. The migration seen in this series is overall consistent to migration patterns observed in other series (50), but this data may contradict the Dennis series (3) (described below) that suggests less symmetry of contact in the lateral compartment in TKAs done with measured resection (i.e. more lateral condylar liftoff).

Dennis et al. (3) reviewed 60 TKAs (40 performed using a MR technique (20 cruciate retaining (CR) and 20 posterior stabilized (PS)) and 20 performed using a GB technique) using fluoroscopy and a 3-D model to determine the incidence of coronal

plane instability. The average femoral condylar lift-off was 1.45mm for the CR MR group, 1.11mm for the PS MR group, and 0.67mm for the GB group. They found that the incidence of femoral lift-off of 1mm or greater was 60% for the CR MR group and 45% for the PS MR group compared to 0% for the GB technique. The authors concluded that rotation of the femoral component is inconsistent when using a MR technique. They also concluded that a GB technique improved coronal plane stability and long-term wear of the TKA. After the dynamic fluoroscopy studies have been collected on all patients at one-year, the TKAs will all be assessed for coronal plane alignment throughout range of motion (as previously described). We will then determine if the difference demonstrated by Dennis et al (3) is in agreement with our patient population. In other words, we will assess if the gap balancing technique does lead to better coronal plane conformity (i.e. less lateral condylar liftoff) than the measured resection technique.

Our results confirmed that a more neutral coronal plane alignment throughout range of motion is achieved post-implant for the majority of TKA patients. This held true regardless of technique utilized to perform the TKA (MR vs. GB). Our hypothesis that the MR technique would show postoperative coronal plane alignment curves more similar to preoperative curves than the GB technique proved to be incorrect. In fact, all patients exhibited characteristics of their preoperative PC pattern post-TKA implantation, though at a lower magnitude.

A significant amount of coronal plane variability throughout a range of motion was demonstrated even in this small cohort. This was consistent with previous work by Young et al (46), though in their much larger series, they did see a much more consistent

pattern of PC curves represented. Intraoperative coronal plane balance of the knee throughout range of motion is difficult to predict based on overall alignment of the lower extremity. Nevertheless, our series did demonstrate a significant correlation for pre-implant varus knees to exhibit more varus through a range of motion after TKA implantation. Some studies have suggested this pattern of post-operative alignment leads to better long-term clinical outcomes, but our study was not designed to assess for this. Still the tendency for varus knees preoperatively to exhibit more varus post-operatively was also congruent with the results demonstrated by Young et al (46).

Our results demonstrate that TKA produces a more neutral alignment throughout a ROM regardless of the preoperative coronal plane alignment throughout ROM. Nevertheless, it is possible that a lack of regard for the variable coronal plane alignment patterns exhibited by patients undergoing TKA may be a contributing factor to decreased functional ability and satisfaction in a subset of TKA patients postoperatively. In other words, there may be something we can influence intra-operatively based on preoperative coronal plane alignment through ROM that may improve patient outcomes. Future study with larger groups of patients is certainly needed to clarify the effects of surgical techniques on kinematic coronal plane alignment and long-term outcomes. Nevertheless it is clear from the current study that features of the pre-implant state appear to influence the post-implant coronal plane alignment through ROM, despite the surgical technique utilized (GB vs. MR) in this small series.

Drawbacks of this study are that it is a single surgeon series (per each technique utilized) and represents a relatively small number of patients. We therefore, may not have been able to demonstrate a significant difference that may in fact exist between the GB and MR techniques for both implant migration and coronal plane alignment throughout ROM. Additionally, due to the small number of patients in the series, outliers in the component migration can significantly effect the mean and influence our results. Nevertheless, our migration results and outliers are consistent with other published series. This study is also slightly underpowered to assess for component migration based on the previously published literature (51) and was powered to assess for lateral condylar liftoff of the femoral component. Certainly, this study needs to be replicated in a much larger patient population to ensure no statistically significant differences exist as well as to correlate the results with clinical outcomes.

5 Conclusion

Total knee arthroplasty (TKA) is a successful and durable operation to relieve pain associated with end-stage arthritis of the knee as well as improve function and quality of life. Nevertheless, as many as 1 in 5 patients are dissatisfied with their TKA after surgery (14). In spite of well understood surgical principles and improved instrumentation and implants, instability is equal to infection as the most common causes for revision TKA in the first five years after TKA and instability accounts for 22% of TKAs revised after five years (16, 18). As such, it is clear that surgical technique in the management of soft tissues is important.

No matter what preference a surgeon has for total knee arthroplasty technique, the goals of surgery are similar: to obtain a knee that is balanced in flexion and extension, restore a neutral mechanical axis of the lower extremity, and obtain well-fixed components in proper alignment in all three planes. Both the GB and MR techniques offer surgeons reproducible and durable methods for obtaining these goals. The work by Dennis et al argues that the gap balancing technique may offer better coronal plane stability than the measured resection technique. Future study of our patient population will include assessment of coronal plane stability of the TKA for both the GB and MR groups. At one year from surgery, all patients will undergo dynamic fluoroscopy and utilizing an existing software model, we will determine component conformity and determine the variations between the groups in terms of lateral condylar liftoff to assess whether Dennis' data can be replicated.

Our hypothesis that the MR technique would produce coronal plane alignment throughout a range of motion that more closely resemble native knee coronal plane alignment throughout a range of motion was not born out by the data from this study. Instead, it appears that post-operative coronal plane alignment throughout a range of motion of the knee is more easily predicted by pre-implant coronal plane alignment throughout a range of motion. This may be explained by the fact that all of the knees in this study were diseased to the point that they were undergoing TKA. It may be that in the diseased knee state, the ligaments, tendons and muscles surrounding the knee are also diseased and will respond in a similar fashion despite the technique (GB or MR) utilized to perform the TKA. A large degree of frontal plane variability existed in the pre-

implant state even among this small number of TKA candidates. Nevertheless, our results demonstrate that TKA reduces individual coronal plane variability and produces a more neutral mechanical axis alignment despite the preoperative coronal plane alignment throughout range of motion. Future study of larger groups of patients is certainly needed to clarify the effects of surgical techniques on kinematic patterns and long-term outcomes. Despite this, it is clear from the current study that features of the pre-implant state appear to influence post-implant kinematics, despite the surgical technique utilized (GB vs. MR) in this small series.

Migration of the components were similar for both the femoral and tibial components in both the MR and GB groups with one exception: external-internal rotation of the tibial component. The migration seen in this series is consistent to migration patterns observed in other series (50, 52). Our results indicate that migration of the tibial component in the GB group tended to be into internal rotation and in the MR group, external rotation. One explanation for this observed difference is that the knees in the MR group were overloaded in the lateral compartment in flexion forcing the tibial component into relative external rotation. Another explanation, that is more in line with the data from Dennis' previous work (3), is that the medial compartment is overloaded and the lateral compartment lifts off in the MR TKAs. As such, instead of femoral rollback (laterally) as one sees in during native knee flexion, the medial compartment asymmetrically loads the tibial component, forcing the component into external rotation. (50). Further study looking at how the knee behaves throughout a range of motion is needed to confirm which of these explanation is more likely.

5 References

1. Michl GL, Katz JN, Losina E. Risk and Risk Perception of Knee Osteoarthritis in the US: Population-based Study. *Osteoarthritis and cartilage / OARS, Osteoarthritis Research Society*. 2015 Nov 7.
2. Saavedra MA, Navarro-Zarza JE, Villasenor-Ovies P, Canoso JJ, Vargas A, Chiapas-Gasca K, et al. Clinical anatomy of the knee. *Reumatologia clinica*. 2012 Dec-2013 Jan;8 Suppl 2:39-45.
3. Sharma L, Song J, Dunlop D, Felson D, Lewis CE, Segal N, et al. Varus and valgus alignment and incident and progressive knee osteoarthritis. *Annals of the rheumatic diseases*. 2010 Nov;69(11):1940-5.
4. Hauk L. Treatment of knee osteoarthritis: a clinical practice guideline from the AAOS. *American family physician*. 2014 Jun 1;89(11):918-20.
5. Meding JB, Keating EM. Overview: long-term followup: predicting the success of a total knee arthroplasty. *Clinical orthopaedics and related research*. 2001 Jul(388):7-9.
6. Ritter MA, Faris PM, Keating EM, Meding JB. Postoperative alignment of total knee replacement. Its effect on survival. *Clinical orthopaedics and related research*. 1994 Feb(299):153-6.
7. Matsuda S, Kawahara S, Okazaki K, Tashiro Y, Iwamoto Y. Postoperative alignment and ROM affect patient satisfaction after TKA. *Clinical orthopaedics and related research*. 2013 Jan;471(1):127-33.
8. Thienpont E, Cornu O, Bellemans J, Victor J. Current opinions about coronal plane alignment in total knee arthroplasty : A survey article. *Acta orthopaedica Belgica*. 2015 Sep;81(3):471-7.
9. Mihalko WM, Whiteside LA, Krackow KA. Comparison of ligament-balancing techniques during total knee arthroplasty. *The Journal of bone and joint surgery American volume*. 2003;85-A Suppl 4:132-5.
10. Mihalko WM, Saleh KJ, Krackow KA, Whiteside LA. Soft-tissue balancing during total knee arthroplasty in the varus knee. *The Journal of the American Academy of Orthopaedic Surgeons*. 2009 Dec;17(12):766-74.
11. Griffin FM, Insall JN, Scuderi GR. Accuracy of soft tissue balancing in total knee arthroplasty. *The Journal of arthroplasty*. 2000 Dec;15(8):970-3.
12. Selvik G. A stereophotogrammetric system for the study of human movements. *Scandinavian journal of rehabilitation medicine Supplement*. 1978;6:16-20.
13. Shi J, Wei Y, Wang S, Chen F, Wu J, Huang G, et al. Computer navigation and total knee arthroplasty. *Orthopedics*. 2014 Jan;37(1):e39-43.
14. Noble PC, Conditt MA, Cook KF, Mathis KB. The John Insall Award: Patient expectations affect satisfaction with total knee arthroplasty. *Clin Orthop Relat Res*. 2006 Nov;452:35-43.
15. Sharkey PF, Hozack WJ, Rothman RH, Shastri S, Jacoby SM. Insall Award paper. Why are total knee arthroplasties failing today? *Clinical orthopaedics and related research*. 2002 Nov(404):7-13.

16. Le DH, Goodman SB, Maloney WJ, Huddleston JI. Current modes of failure in TKA: infection, instability, and stiffness predominate. *Clinical orthopaedics and related research*. 2014 Jul;472(7):2197-200.
17. Parratte S, Pagnano MW. Instability after total knee arthroplasty. *The Journal of bone and joint surgery American volume*. 2008 Jan;90(1):184-94.
18. Cuckler JM. When it doesn't work: mechanisms of TKA failure. *Orthopedics*. 1999 Sep;22(9):871-2.
19. Incavo SJ, Wild JJ, Coughlin KM, Beynon BD. Early revision for component malrotation in total knee arthroplasty. *Clinical orthopaedics and related research*. 2007 May;458:131-6.
20. Romero J, Stahelin T, Binkert C, Pfirrmann C, Hodler J, Kessler O. The clinical consequences of flexion gap asymmetry in total knee arthroplasty. *The Journal of arthroplasty*. 2007 Feb;22(2):235-40.
21. Babazadeh S, Dowsey MM, Stoney JD, Choong PF. Gap balancing sacrifices joint-line maintenance to improve gap symmetry: a randomized controlled trial comparing gap balancing and measured resection. *The Journal of arthroplasty*. 2014 May;29(5):950-4.
22. Singh VK, Varkey R, Trehan R, Kamat Y, Raghavan R, Adhikari A. Functional outcome after computer-assisted total knee arthroplasty using measured resection versus gap balancing techniques: a randomised controlled study. *Journal of orthopaedic surgery*. 2012 Dec;20(3):344-7.
23. Dennis DA, Komistek RD, Kim RH, Sharma A. Gap balancing versus measured resection technique for total knee arthroplasty. *Clinical orthopaedics and related research*. 2010 Jan;468(1):102-7.
24. Katz MA, Beck TD, Silber JS, Seldes RM, Lotke PA. Determining femoral rotational alignment in total knee arthroplasty: reliability of techniques. *J Arthroplasty*. 2001 Apr;16(3):301-5.
25. Babazadeh S, Dowsey MM, Stoney JD, Choong PF. Gap balancing sacrifices joint-line maintenance to improve gap symmetry: a randomized controlled trial comparing gap balancing and measured resection. *J Arthroplasty*. 2014 May;29(5):950-4.
26. Heesterbeek PJ, Jacobs WC, Wymenga AB. Effects of the balanced gap technique on femoral component rotation in TKA. *Clinical orthopaedics and related research*. 2009 Apr;467(4):1015-22.
27. Arima J, Whiteside LA, McCarthy DS, White SE. Femoral rotational alignment, based on the anteroposterior axis, in total knee arthroplasty in a valgus knee. A technical note. *J Bone Joint Surg Am*. 1995 Sep;77(9):1331-4.
28. Poilvache PL, Insall JN, Scuderi GR, Font-Rodriguez DE. Rotational landmarks and sizing of the distal femur in total knee arthroplasty. *Clin Orthop Relat Res*. 1996 Oct(331):35-46.
29. Whiteside LA, Arima J. The anteroposterior axis for femoral rotational alignment in valgus total knee arthroplasty. *Clin Orthop Relat Res*. 1995 Dec(321):168-72.
30. Pagnano MW, Hanssen AD. Varus tibial joint line obliquity: a potential cause of femoral component malrotation. *Clinical orthopaedics and related research*. 2001 Nov(392):68-74.

31. Griffin FM, Insall JN, Scuderi GR. The posterior condylar angle in osteoarthritic knees. *J Arthroplasty*. 1998 Oct;13(7):812-5.
32. Berger RA, Rubash HE, Seel MJ, Thompson WH, Crossett LS. Determining the rotational alignment of the femoral component in total knee arthroplasty using the epicondylar axis. *Clin Orthop Relat Res*. 1993 Jan(286):40-7.
33. Churchill DL, Incavo SJ, Johnson CC, Beynnon BD. The transepicondylar axis approximates the optimal flexion axis of the knee. *Clinical orthopaedics and related research*. 1998 Nov(356):111-8.
34. Stiehl JB, Abbott BD. Morphology of the transepicondylar axis and its application in primary and revision total knee arthroplasty. *The Journal of arthroplasty*. 1995 Dec;10(6):785-9.
35. Witoolkollachit P, Seubchompoo O. The comparison of femoral component rotational alignment with transepicondylar axis in mobile bearing TKA, CT-scan study. *Journal of the Medical Association of Thailand = Chotmaihet thangphaet*. 2008 Jul;91(7):1051-8.
36. Miller MC, Berger RA, Petrella AJ, Karmas A, Rubash HE. Optimizing femoral component rotation in total knee arthroplasty. *Clinical orthopaedics and related research*. 2001 Nov(392):38-45.
37. Scuderi GR, Komistek RD, Dennis DA, Insall JN. The impact of femoral component rotational alignment on condylar lift-off. *Clinical orthopaedics and related research*. 2003 May(410):148-54.
38. Insall JN, Scuderi GR, Komistek RD, Math K, Dennis DA, Anderson DT. Correlation between condylar lift-off and femoral component alignment. *Clinical orthopaedics and related research*. 2002 Oct(403):143-52.
39. Hanada H, Whiteside LA, Steiger J, Dyer P, Naito M. Bone landmarks are more reliable than tensioned gaps in TKA component alignment. *Clinical orthopaedics and related research*. 2007 Sep;462:137-42.
40. Fehring TK. Rotational malalignment of the femoral component in total knee arthroplasty. *Clinical orthopaedics and related research*. 2000 Nov(380):72-9.
41. Dennis DA. Measured resection: an outdated technique in total knee arthroplasty. *Orthopedics*. 2008 Sep;31(9):940, 3-4.
42. Jerosch J, Peuker E, Philipps B, Filler T. Interindividual reproducibility in perioperative rotational alignment of femoral components in knee prosthetic surgery using the transepicondylar axis. *Knee Surg Sport Tr A*. 2002 May;10(3):194-7.
43. Kinzel V, Ledger M, Shakespeare D. Can the epicondylar axis be defined accurately in total knee arthroplasty? *Knee*. 2005 Aug;12(4):293-6.
44. Dennis DA, Komistek RD, Kim RH, Sharma A. Gap balancing versus measured resection technique for total knee arthroplasty. *Clin Orthop Relat Res*. 2010 Jan;468(1):102-7.
45. Scuderi GR, Bourne RB, Noble PC, Benjamin JB, Lonner JH, Scott WN. The new Knee Society Knee Scoring System. *Clinical orthopaedics and related research*. 2012 Jan;470(1):3-19.
46. Young KL, Dunbar MJ, Richardson G, Astephen Wilson JL. Intraoperative passive knee kinematics during total knee arthroplasty surgery. *Journal of*

orthopaedic research : official publication of the Orthopaedic Research Society.
2015 Nov;33(11):1611-9.

47. Hatfield GL, Hubley-Kozey CL, Astephen Wilson JL, Dunbar MJ. The effect of total knee arthroplasty on knee joint kinematics and kinetics during gait. *The Journal of arthroplasty*. 2011 Feb;26(2):309-18.
48. Deluzio KJ, Astephen JL. Biomechanical features of gait waveform data associated with knee osteoarthritis: an application of principal component analysis. *Gait & posture*. 2007 Jan;25(1):86-93.
49. Matsumoto T, Muratsu H, Kawakami Y, Takayama K, Ishida K, Matsushita T, et al. Soft-tissue balancing in total knee arthroplasty: cruciate-retaining versus posterior-stabilised, and measured-resection versus gap technique. *International orthopaedics*. 2014 Mar;38(3):531-7.
50. Wilson DA, Hubley-Kozey CL, Astephen Wilson JL, Dunbar MJ. Pre-operative muscle activation patterns during walking are associated with TKA tibial implant migration. *Clinical biomechanics*. 2012 Nov;27(9):936-42.
51. Molt M, Toksvig-Larsen S. Similar early migration when comparing CR and PS in Triathlon TKA: A prospective randomised RSA trial. *The Knee*. 2014 Oct;21(5):949-54.
52. Regner L, Carlsson L, Karrholm J, Herberts P. Tibial component fixation in porous- and hydroxyapatite-coated total knee arthroplasty: a radiostereo metric evaluation of migration and inducible displacement after 5 years. *The Journal of arthroplasty*. 2000 Sep;15(6):681-9.

Appendix A: Power analysis (based on work by Dr. Dennis et al (3))

Outcome measure: incidence of coronal instability (defined as Femoral lift-off > 1.0mm)

Intervention group (Gap balancing) : 0/20 (0%)

Control group (measured resection): 11/20 (55%)

Alpha = 0.05

Beta (Power) = 80%

Allocation ratio 1:1

Require 11 patients per group (with 10% inflation for attrition = 12)

Appendix B: Copyright Permission

License Number	3804390336594
License date	Feb 08, 2016
Licensed Content Publisher	John Wiley and Sons
Licensed Content Publication	Journal of Orthopaedic Research
Licensed Content Title	Intraoperative passive knee kinematics during total knee arthroplasty surgery
Licensed Content Author	Kathryn L. Young, Michael J. Dunbar, Glen Richardson, Janie L. Astephen Wilson
Licensed Content Date	Jun 3, 2015
Pages	9
Type of use	Dissertation/Thesis
Requestor type	University/Academic
Format	Print and electronic
Portion	Figure/table
Number of figures/tables	1
Original Wiley figure/table number(s)	Figure 3
Will you be translating?	No
Title of your thesis / dissertation	Effect of Surgical technique on coronal plane motion in TKA
Expected completion date	Feb 2016
Expected size (number of pages)	60
Requestor Location	Mayo Dept of Orthopedics Mayo Clinic 200 First Street SW; West 14 Rochester, MN 55905 United States Attn: Karen Fasbender
Customer VAT ID	
Billing Type	Invoice
Billing Address	Mayo Dept of Orthopedics Mayo Clinic 200 First Street SW; West 14 Rochester, MN 55905 United States Attn: Karen Fasbender

KNEE SOCIETY SCORE

•to be completed by staff

PAIN	Right	Left
None	50	50
Mild or Occasional	45	45
Stairs Only	40	40
Walking and Stairs	30	30
Moderate Occasional	20	20
Moderate Continual	10	10
Severe	0	0
Range of Motion	Right	Left
Start of Flexion (Degrees)- Extension		
End of Flexion (Degrees)		
Anterior/ Posterior Instability: Measured at 90°		
	R	L
None		
Moderate <5mm		
Severe >5mm		
Medial/ Lateral Instability: Measured in Full Extension		
	R	L
None		
Little <5mm		
Moderate 5mm		
Severe >5mm		
Flexion Contracture		
	R	L
1-5°		
6-10°		
11-15°		
>15°		
Extension Lag		
	R	L
<10°		
10 20°		
>20°		
Walking	Right	Left
Unlimited	50	50
>10 blocks	40	40
5-10 blocks	30	30
<5 blocks	20	20
House Bound	10	10
Unable	0	0
Stairs	Right	Left
Normal Up and Down	50	50
Normal Up; Down with Rail	40	40
Up and Down with Rail	30	30
Up with Rail; Unable Down	15	15
Unable	0	0
Support	Right	Left
None	0	0
Cane	-5	-5
Two Crutches	-10	-10
Crutches or Walker	-20	-20

Charnley Functional Classification

- | | | | | | |
|---|----|----|----|----|----|
| A | B1 | B2 | C1 | C2 | C3 |
|---|----|----|----|----|----|
- A: Unilateral Knee Arthritis
 B1: Unilateral TKA, Opposite Knee Arthritic
 B2: Bilateral TKA
 C1: TKA, but remote arthritis affecting ambulation
 C2: TKA, but medical condition affecting ambulation
 C3: Unilateral or Bilateral TKA with Unilateral or bilateral THA

RADIOGRAPHIC FINDINGS

Alignment: Measured on AP Xray		
	R	L
Neutral: 2-10° valgus		
Varus: <2° Valgus		
Valgus: >10° Valgus		

Comments: _____

 Examiner: _____

Curriculum Vitae and Bibliography

Kevin I. Perry, MD

1. Personal Information

2. Present Academic Rank and Position

Senior Associate Consultant and Assistant Professor of Orthopedic Surgery, Mayo Clinic,

Rochester, Minnesota

08/2015 - Present

3. Education

Swarthmore College, Swarthmore, Pennsylvania - BA, Economics 2000 - 2004

Saint Louis University Medical School, Saint Louis, Missouri - MD 2005 - 2009

Mayo Clinic, Department of Orthopedic Surgery - Resident 2009 - 2014

London Health Science Centre, London, Ontario, Canada - Clinical/Research

Fellowship, Adult Reconstruction

08/2014 - 07/2015

4. Certifications

Board Certifications

American Board of Orthopaedic Surgery (ABOS)

Part I

5. Licensure

Minnesota 53139 (Medical) 02/2015 - 02/2016

6. Honors/Awards

Orthopedic Achievement Award for Clinical Competency - Orthopedic, Mayo

Clinic

06/2014

7. Military Service

None

8. Previous Professional Positions and Major Appointments

Mayo Clinic Scholar - Department of Orthopedic Surgery, Mayo Clinic,

Rochester, Minnesota

06/2014 - 08/2015

9. Professional & Community Memberships, Societies and Services

Professional Memberships & Services

American Medical Association

Member 2005 - Present

American Association of Orthopaedic Surgeons

Member 2009 - Present

American Association of Hip and Knee Surgeons

Member 2014 - Present

Journal Other Responsibilities

Bone and Joint Journal

Article Reviewer, Rochester, Minnesota 08/2013 - Present

Community Memberships & Services

Saint Louis Fire Department

Volunteer EMT-B, Saint Louis, Missouri 2004 - 2009

RE-AIMS Aug 28, 2015

Volunteer EMT-B, Saint Louis, Missouri 2004 - 2009

10. Educational Activities

A. Curriculum/Course Development

B. Teaching

C. Mentorship

Individual and Position Timeframe &

Description

Outcomes Current Status

D. Academic Career Development

11. Institutional/Departmental Administrative Responsibilities, Committee

Memberships and Other Activities

Mayo Clinic in Rochester

Department of Orthopedics Education Committee

Committee Member, Rochester, Minnesota 07/2012 - Present

12. Presentations Extramural

National/International

Oral

Minimal Preoperative Degenerative Arthritis May Not Predict Poor TKA Outcome.

AAOS Annual Meeting

San Francisco, California

03/2012

Decrease in Dislocation after Primary THA With Use of Larger Femoral Heads:

An Update on a Previous Series.

(Perry K, Sierra R, Harmsen S, Berry D)

AAOS Annual Meeting

Chicago, Illinois

02/2013

Decrease in Dislocation after Primary THA With Use of Larger Femoral Heads:

An Update on a Previous Series.

(Perry K, Sierra R, Harmsen S, Berry D)

Mid-America Orthopedic Association meeting

Amelia Island, Florida

04/2013

Caution! High Rate of Positive Cultures in Referred Patients with Antibiotic

Spacers.

(Perry K, Sproul R, Sierra R, Fehring T, Hanssen A)

2013 AAHKS meeting

Dallas, Texas

11/2013

Patient Reported vs. Administered Questionnaire: Is there a difference in pain and function after THA and TKA?

(Perry K, Loechler Y, Sierra R)

2014 ORS meeting

New Orleans, Louisiana

03/2014

Patient Reported vs. Administered Questionnaire: Is there a difference in pain and function after THA and TKA?

(Perry K, Loechler Y, Sierra R)

2014 Mid-America Orthopedic Association meeting

San Antonio, Texas

04/2014

Results of Modular Cementless Femoral Reconstruction in Primary Total Hip Arthroplasty for Treatment of Developmental Dysplasia of the Hip

(Perry K, Nett M, Hanssen A, Hull J, Berry D)

Mid-America Orthopedic Association meeting

San Antonio, Texas

04/2014

Caution! High Rate of Positive Cultures in Referred Patients with Antibiotic Spacers.

(Perry K, Sproul R, Sierra R, Fehring T, Hanssen A)

Mid-America Orthopedic Association meeting

San Antonio, Texas

04/2014

Caution! High Rate of Positive Cultures in Referred Patients with Antibiotic Spacers.

(Perry K, Sproul R, Sierra R, Fehring T, Hanssen A)

2014 ISAR meeting

Cambridge, Massachusetts

05/2014

Poster

Decrease in Dislocation Rates With Use of Larger Femoral Heads

ISAR

Stratford-upon-Avon, United Kingdom

06/2013

Poster: Fifteen Year Results of an Inset Biconvex Patellar Design in Primary Total

Knee Arthroplasty: An update on a previous series.

(Perry K, MacDonald S, McCalden R)

2015 The Canadian Orthopaedic Association(COA)meeting

Vancouver, British Columbia, Canada

06/2015

Regional

Oral

Minimal Preoperative Degenerative Arthritis May Not Predict Poor TKA Outcome

MAOA 2012

Bonita Springs, Florida

04/2012

Use of a Modular Fluted Femoral Component in Revision Total Hip Arthroplasty

Following Resection of A Previously Infected Total Hip: Minimum 5-Year Follow-up

MAOA 2013

Amelia Island, Florida

04/2013

13. Visiting Professorships

14. Clinical Practice, Interests, and Accomplishments

Primary Hip and Knee Arthroplasty

Revision Hip and Knee Arthroplasty

Infection

15. Research Interests

Gap Balancing vs. Measured Resection for TKA

Intraoperative Knee Kinematics during TKA

Pressure sensor technology in TKA

Patient reported outcome measures

16. Educational Practice, Interests, and Accomplishments

Resident and fellow education in primary and revision hip and knee arthroplasty

17. Research Grants Awarded

18. Patents

Title Patent Number Date filed Date issued

19. Bibliography

Peer-reviewed Articles

Perry K, Hanssen A. Hybrid fixation for primary total knee arthroplasty. Techniques in Total Knee Arthroplasty. Sept. 2011; 10:143-147.

1.

Kakar S, Swann RP, **Perry KI**, Wood-Wentz CM, Shin AY, Moran SL. Functional and radiographic outcomes following distal ulna implant arthroplasty. J Hand Surg Am. 2012 Jul; 37(7):1364-71. PMID:22721459. DOI:10.1016/j.jhsa.2012.03.026.

2.

3.

Perry KI, Berry DJ. Femoral considerations for total hip replacement in hip dysplasia.

Orthop Clin North Am. 2012 Jul; 43(3):377-86. PMID:22819165. DOI:10.1016/j.ocl.2012.05.010.

3.

Abdel MP, **Perry KI**, Morrey ME, Steinmann SP, Sperling JW, Cass JR. Arthroscopic management of native shoulder septic arthritis. J Shoulder Elbow Surg. 2013; 22(3):418-421.

4.

Perry KI, Trousdale RT, Sierra RJ. Hip dysplasia in the young adult: an osteotomy solution. Bone Joint J. 2013 Nov; 95-B(11 Suppl A):21-5. PMID:24187346.

DOI:10.1302/0301-620X.95B11.32633.

5.

Perry K, Abdel M, Rose P, Lewallen D, Sim F. Innovative methods of reconstruction after pelvic tumor resection. Current Surgery Reports. 2014; 2:41.

6.

Perry KI, MacDonald SJ. Articulating choices in total hip arthroplasty: why's, wherefores, and caveats. Semin Arthroplasty. 2015; 26(1):2-5.

7.

Houdek MT, **Perry KI**, Wyles CC, Berry DJ, Sierra RJ, Trousdale RT. Use of a modular tapered fluted femoral component in revision total hip arthroplasty following resection of a previously infected total hip: minimum 5-year follow-up. J Arthroplasty. 2015 Mar;

30(3):435-8. Epub 2014 Sep 06. PMID:25534955. DOI:10.1016/j.arth.2014.08.012.

8.

Perry KI, Strasser NL, Harmsen WS, Pagnano MW, Trousdale RT. Minimal Preoperative Degenerative Arthritis May Not Predict Poor TKA Outcome. Orthopedics. 2015 Aug 1;

38(8):e681-4. PMID:26270753. DOI:10.3928/01477447-20150804-54.

9.

Book Chapters

Perry KI. The Neuromusclar Hip. In: Callaghan J, Beale P, Clohisy J, Della Valle C, Rosenberg A, Rubash H. The Adult Hip 3rd ed. Philadelphia: LWW; 2014. (Book chapter)

1.

